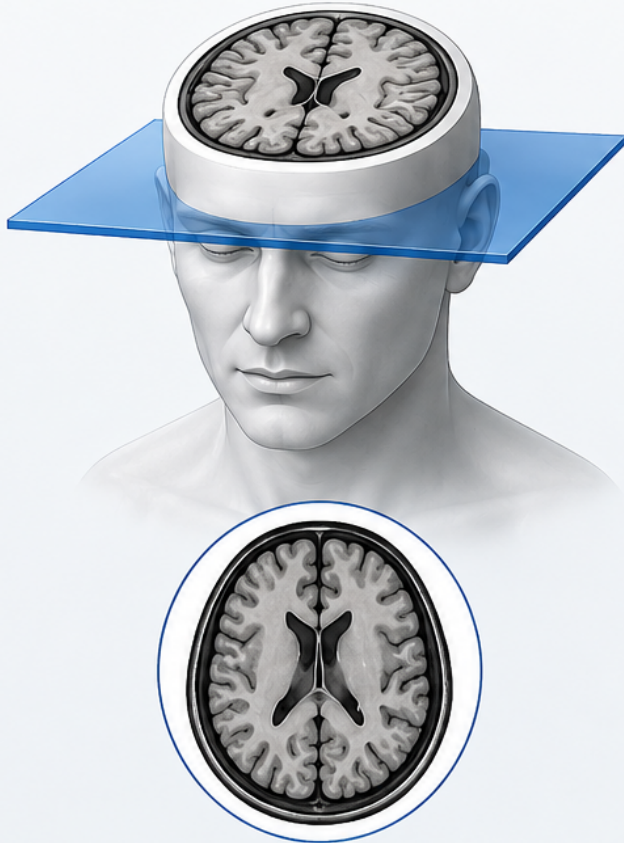


# IMAGING PLANES

## AXIAL PLANE

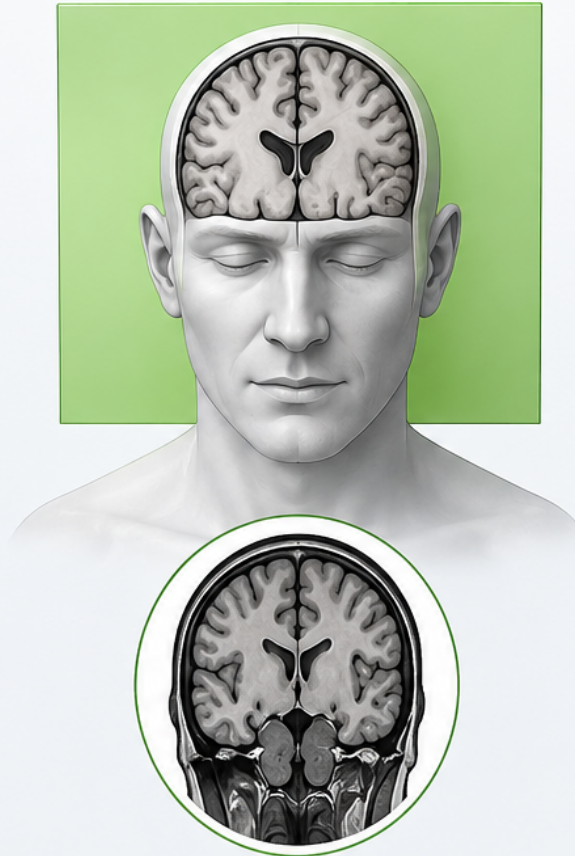
Horizontal Slice (Top View)



Axial plane divides the body into **superior** (upper) and **inferior** (lower) parts.

## CORONAL PLANE

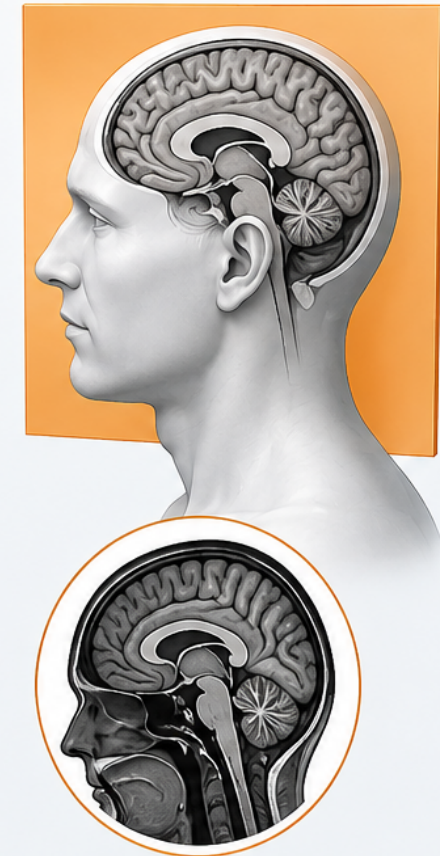Frontal Slice (Front View)



Coronal plane divides the body into **anterior** (front) and **posterior** (back) parts.

## SAGITTAL PLANE

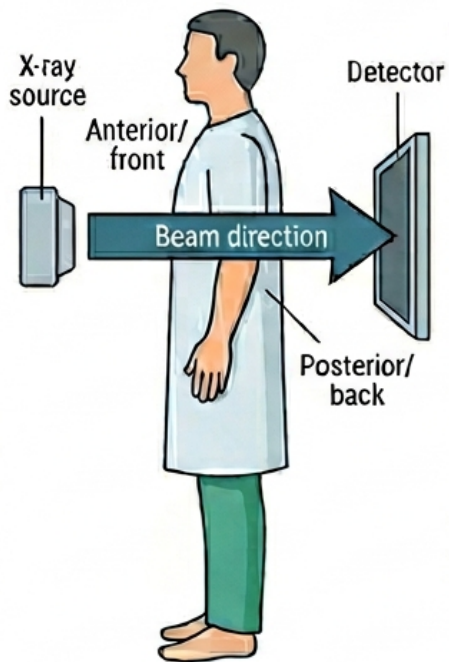
Lateral Slice (Side View)



Sagittal plane divides the body into **left** and **right** parts.

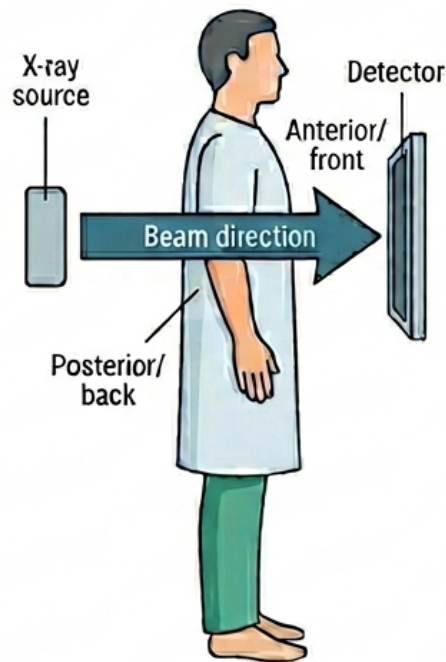
# X-RAY PROJECTIONS

## AP – Anteroposterior



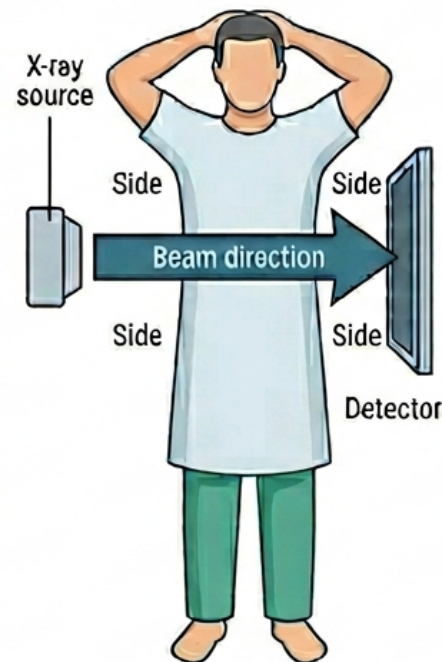
Beam enters anterior/front and exits posterior/back.

## PA – Posteroanterior



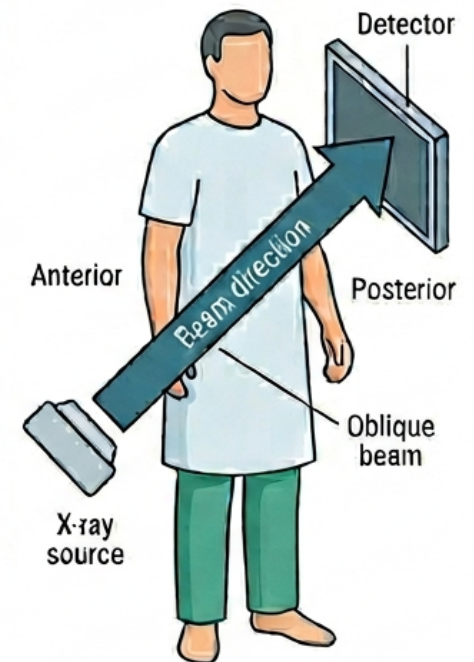
Beam enters posterior/back and exits anterior/front.

## Lateral



Beam enters one side and exits the opposite side.

## Oblique



Beam enters and exits at an angle.